

Synchronous Adenocarcinoma and Mucosa-associated Lymphoid Tissue (MALT) Lymphoma in a Single Stomach

Sun-Young Lee¹, Jae J. Kim², Jun Haeng Lee², Young-Ho Kim², Poong-Lyul Rhee², Seung Woon Paik², Jong Chul Rhee² and Young Hyeon Ko³

¹Department of Internal Medicine, Konkuk University College of Medicine, ²Department of Medicine and ³Department of Pathology, Samsung Medical Center, Sungkyunkwan University School of Medicine, Seoul, Korea

Received May 12, 2005; accepted August 10, 2005

Background: Synchronous gastric adenocarcinoma and primary gastric mucosa-associated lymphoid tissue (MALT) lymphoma are rare, and the characteristics of these tumors are still unclear.

Methods: Histology of endoscopic and surgical specimens of 6012 gastric adenocarcinoma and 25 primary gastric MALT lymphoma cases were reviewed.

Results: Five cases of synchronous tumors were found among 25 primary gastric MALT lymphoma patients (20.0%) and among 6012 gastric adenocarcinoma patients (8.3%). *Helicobacter pylori* was detected only in two cases (40.0%) of these five synchronous cases. In only one case, two types of malignant cells were mingled each other as a colliding tumor. In other four cases, two pathologies coexisted separately. These two types of malignant tumors were not distinguished by endoscopic or gross findings.

Conclusions: Although gastric adenocarcinoma coexists with MALT lymphoma at a relatively high frequency, synchronous carcinoma can be misinterpreted as a multifocal separated lesion of MALT lymphoma owing to their macroscopic resemblance. Therefore, gastric MALT lymphoma patients should be carefully examined by endoscopy, and any suspicious area must be biopsied considering the possibility of coexisting adenocarcinoma. In addition, etiologies other than *H. pylori* should be considered in these synchronous tumors.

Key words: gastric cancers – adenocarcinoma – lymphoma – mucosa-associated lymphoid tissue

INTRODUCTION

B-cell lymphomas of mucosa-associated lymphoid tissue (MALT) represent a distinct entity within extranodal non-Hodgkin's lymphoma (1). This tumor has peculiar clinicopathologic features that are different from those of nodal type B-cell lymphomas and has been included in the recently proposed REAL classification within the marginal zone B-cell lymphoma subgroup (2). It is characterized by prominent and often multifocal lymphoepithelial lesions with dense, diffuse infiltrates of centrocyte-like cells within the lamina propria (3).

Recently, it is considered that an extraordinarily large number of patients with other malignancies are observed in cases of MALT lymphoma including simultaneous presence of adenocarcinoma and primary MALT lymphoma in a single stomach (4). A previous study reported that the incidence of coexisting

primary malignant lymphoma and adenocarcinoma of the stomach occurs in 0.08% (2 of 2438 adenocarcinoma cases) (5). Since it is difficult to distinguish adenocarcinoma and MALT lymphoma macroscopically (6,7), virtually all cases of these coexisting tumors are not diagnosed before surgery (8). These could be also explained by the low rate of accurate diagnosis for the presence of coexisting lymphoma. The accuracy of endoscopic biopsies from gastric lymphoma is not satisfactory and sampling may be problematic when there is a considerable reactive lymphoid infiltration adjoining the lymphoma (9). Moreover, errors may also occur in distinguishing lymphoma from poorly differentiated carcinoma (8). In addition, obliteration of normal glands by infiltrating centrocyte-like cells may result in scattered isolated benign epithelial cells that should not be interpreted as being cells from an infiltrative diffuse-type adenocarcinoma (10).

Although the synchronous development of these two tumors might be a coincidence rather than a direct relationship, increased detection rates may be the result of increased systemic surveillance. Previous studies proposed that these synchronous tumors develop because one preexisting tumor provokes the other, or the two tumors arise independently

For reprints and all correspondence: Jae J. Kim, Department of Medicine, Samsung Medical Center, Sungkyunkwan University School of Medicine, 50, Irwon-dong, Gangnam-gu, Seoul 135-710, Korea.
E-mail: jjkim@smc.samsung.co.kr

as a result of the same carcinogenic action (11). It has also been suggested that *Helicobacter pylori* might play an important role in the development of both lymphoma and adenocarcinoma, and thus provide a unifying theory for their common pathogenesis (10). These tumors are usually known to collide (10–15) and some concluded that MALT lymphoma precedes adenocarcinoma because most of the adenocarcinoma were smaller and penetrated less than coexisting MALT lymphoma (13,16,17). However, the details have not been clarified because of the rarity of the condition.

Here, we present an analysis of the findings of synchronous gastric adenocarcinoma and primary gastric MALT lymphoma cases established by surgical specimens.

PATIENTS AND METHODS

Cases of synchronous gastric adenocarcinoma and primary gastric MALT lymphoma were retrieved from 6012 gastric adenocarcinoma patients and 25 primary gastric MALT lymphoma patients who were operated between October 1994 and June 2003 at the Samsung Medical Center. Primary gastric MALT lymphoma was referred to the surgical department only when the *H. pylori* eradication therapy has failed or when the stage was greater than stage IE. This retrospective study was carried out in accordance with the ethical guidelines of the Helsinki Declaration revised in 1989. Informed consents for the endoscopic procedures and operations were obtained from all of the patients.

The demographic data of the patients and the pathologic results of the endoscopic forceps biopsies and surgical specimens were reviewed. Macroscopic appearance of gastric cancer was recorded according to the Japanese classification of gastric cancer (18). Gastric adenocarcinoma was classified as either intestinal or diffuse type by Lauren’s classification (19). Primary gastric MALT lymphoma was classified according to the criteria of the REAL classification (2). The size of each tumor was calculated by measuring the longest diameter and the diameter perpendicular to it. The depth of the tumor was recorded by one of the four layers of the stomach. Collision tumor was defined when one neoplasm grew into the other with a distinct separate areas of both tumors.

All specimens were reviewed after routine hematoxylin and eosin staining and Giemsa staining for *H. pylori*. Presence of

H. pylori infection was confirmed by either Giemsa staining or serology (IgG *H. pylori* antibody). Negativity for *H. pylori* infection was accepted when both tests were negative.

RESULTS

INCIDENCE AND CLINICAL FINDINGS

The median age of the gastric adenocarcinoma group was 55.8 ± 12.0 years and that of the primary gastric MALT lymphoma group was 51.1 ± 14.3 years, showing no significant difference between two groups (*P* = 0.053). In aspect of sex distribution, the gastric adenocarcinoma group was composed of 3986 male patients and 2026 female patients while the primary gastric MALT lymphoma group was composed of 12 male patients and 13 female patients, showing no significant difference between two groups (*P* = 0.059).

Five cases of synchronous gastric adenocarcinoma and MALT lymphoma were identified among 25 primary gastric MALT lymphoma patients (20.0%) and among 6012 gastric adenocarcinoma patients (8.3%). Median age was 59.4 years and the sex distribution was M : F = 4 : 1. None of the patients had B symptoms such as fever, night sweating or weight loss. Laboratory testing for platelet count, erythrocyte sedimentation rate and lactic dehydrogenase at the time of diagnosis were within normal limits. *H. pylori* was positive in only two patients (40.0%). Curative surgical resections were performed in these patients since they had no evidence of distant metastasis. None of them has suffered from recurrence yet (Table 1).

PREOPERATIVE ENDOSCOPIC FINDINGS

In four cases (80.0%), preoperative endoscopic finding revealed a depressed ulcerating lesion with abnormal clubbing folds, uneven base and irregular margin that lead to diagnosis as early gastric cancer stage IIc. In one case (20.0%), a huge ulcero-infiltrating mass with easy touch bleeding was noticed. This case was diagnosed as an advanced gastric cancer Bormann type III. The possibility of lymphoma was not raised by endoscopic finding in all of these five cases, and the regions of adenocarcinoma and MALT lymphoma were not distinguished macroscopically. Only one case was diagnosed as coexisting adenocarcinoma and MALT lymphoma before operation by endoscopic biopsy. In the remaining four

Table 1. Clinical data and endoscopic findings

| Case | Sex/age | Endoscopic diagnosis | Endoscopic biopsy | <i>H. pylori</i> infection | Treatment | Follow-up (months) |
|------|---------|----------------------|---------------------------------|----------------------------|-----------|--------------------|
| 1 | M/54 | EGC IIc | Adenocarcinoma | Positive | STG | 16 |
| 2 | M/60 | EGC IIc | Adenocarcinoma | Negative | TG | 22 |
| 3 | M/62 | EGC IIc | Adenocarcinoma MALT lymphoma | Positive | TG | 18 |
| 4 | M/73 | AGC B-III | Adenocarcinoma | Negative | STG | 23 |
| 5 | F/48 | EGC IIc | Adenocarcinoma | Negative | STG | 19 |

EGC, early gastric cancer; AGC, advanced gastric cancer; STG, subtotal gastrectomy; TG, total gastrectomy.

Table 2. Pathologic findings of synchronous carcinoma and lymphoma

| Case | Type of carcinoma | Locus and size of carcinoma | Depth of carcinoma | Locus and size of lymphoma | Depth of lymphoma |
|------|-----------------------------|---|---------------------|---|-------------------|
| 1 | EGC (Signet ring cell type) | Low-body, GC 1.0 × 0.6 cm ² | Mucosa | Multifocal Unmeasurable | Submucosa |
| 2 | EGC (WD, intestinal type) | Mid-body 2.6 × 2.0 cm ² | Submucosa | Multifocal Unmeasurable | Submucosa |
| 3 | EGC (WD, intestinal type) | Angle, post 2.0 × 1.6 cm ² | Mucosa Collision | Multifocal Unmeasurable | Submucosa |
| 4 | EGC (MD, intestinal type) | Low-body, LC 2.6 × 1.9 cm ² | Mucosa | Low-body, GC 3.1 × 2.7 cm ² | Submucosa |
| 5 | EGC (PD, diffuse type) | Low-body, post 3.2 × 1.2 cm ² | Mucosa | Low-body, post 0.4 × 0.2 cm ² | Mucosa |

EGC, early gastric cancer; WD, well differentiated; MD, moderately differentiated; PD, poorly differentiated; GC, greater curvature side; post, posterior wall.

cases, synchronous MALT lymphoma was diagnosed only after the surgical resection. In these cases, an adenocarcinoma biopsy result prompted surgical resection and revealed MALT lymphoma in a single stomach. Even after the resection, the region of adenocarcinoma and MALT lymphoma were not exactly distinguished by gross finding owing to their macroscopic resemblance.

HISTOLOGICAL FINDINGS

All five specimens revealed typical characteristic features of low-grade B-cell MALT lymphoma with lymphoepithelial lesions. Intestinal type was the most common type of adenocarcinoma (Table 2). Only one case revealed collision (Fig. 1).

In three cases of MALT lymphoma, we assumed the size of lymphoma as a sum of infiltrated area because of a multifocal appearance in the surgically resected specimen. Four early gastric adenocarcinoma cases were of a smaller size than the coexisting lymphoma, whereas one case of poorly differentiated adenocarcinoma of the diffuse type was not. The depth of the adenocarcinoma was equal or less than that of the lymphoma in all cases.

DISCUSSION

We have found five cases of synchronous gastric adenocarcinoma and MALT lymphoma among 6012 gastric adenocarcinoma patients (8.3%) and among 25 primary gastric MALT lymphoma patients (20.0%), which reveal a relatively high frequency. Although these synchronous tumors are usually known to collide (10–15), most of these synchronous tumors were discrete in the present study. Considering that the true collision tumors are defined as two coexisting tumors that have developed at different sites and have invaded each other in the region of contact during their growth (20), there might be distinct separate areas of both tumors. When these synchronous tumors do not collide to each other like our result, it is more difficult to diagnosis before the gastrectomy since the tumors are separated in a single stomach. Therefore, endoscopic biopsies are needed in all suspicious lesions unless there is a close

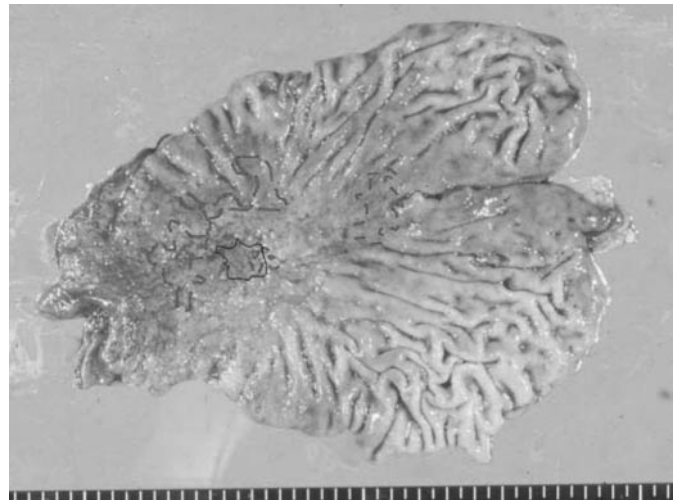


Figure 1. Gross finding of collision tumor (Case 3). Dotted line indicates the area of low-grade marginal zone B-cell lymphoma of MALT type. Connected line indicates the area of adenocarcinoma. Colliding was observed only in a subtle part of these synchronous tumors.

juxtaposition of the two types of tumors without any normal tissue between them. Our finding suggests the importance of multiple biopsies in diagnosing non-colliding tumors.

It has been reported that the majority of synchronous gastric adenocarcinoma are of the intestinal type and that others are extremely rare (8,10–14,17,21–23). In fact, only few cases of synchronous signet ring cell carcinoma have been reported to date (15). In the present study, diffuse-type and signet ring cell type were noticed next to intestinal-type. In aspect of *H. pylori* infection, the majority of patients (60.0%) were negative by both histological examination and serology study. This finding is contrary to those of previous studies, which have reported that almost all of these synchronous tumors are infected with *H. pylori* (8,10,14,15,21,22,24). A close association between *H. pylori* infection and gastric malignancies, not only with adenocarcinomas but also with lymphomas was reported in an epidemiological study (25). However, like our result, not all synchronous gastric adenocarcinoma and lymphoma cases

are clearly associated with *H. pylori* (17). There is no evidence of *H. pylori* infection in ~5–10% of gastric MALT lymphomas (26), and it is reported that the infection rate is higher in Eastern hemisphere than Western (17). Although the cause is under investigation, it is assumed that there is a subgroup of MALT lymphoma that arise *de novo* independent of *H. pylori* (27). It is likely that factors other than *H. pylori* play an important role in the development of both gastric adenocarcinoma and primary gastric MALT lymphoma. The etiology may be complex and multifactorial or there might be some common factors influencing these two gastric malignancies. For example, an underlying genetic instability could possibly lead to the simultaneous development of both tumors or provoke a high incidence of secondary cancers in patients with primary low-grade MALT lymphoma (25). Future longitudinal follow-up study is needed to clarify these issues.

In the present study, most of the adenocarcinoma were smaller and penetrated less than coexisting MALT lymphoma like previous reports (8,11,13,17,21). These findings suggest that the adenocarcinoma might have developed after the MALT lymphoma through carcinomatous changes brought about by the chronic irritation of the mucosa (11). In this point of view, lymphoma-associated immunosuppressive state may be a key to the subsequent development of gastric carcinoma (9). Accordingly, there is a possibility that the presence of a primary gastric MALT lymphoma increases the risk of developing gastric adenocarcinoma, as has been suggested by previous studies (13,16,17).

In conclusion, since there are no typical endoscopic findings or gross findings of adenocarcinoma different from MALT lymphoma, preoperative diagnosis of this synchronous tumor is very difficult. Therefore, an identification of such coexisting MALT lymphoma can be difficult and might be misinterpreted as adenocarcinoma. Taken together, multiple endoscopic biopsies should be performed in gastric adenocarcinoma patients to detect coexisting synchronous MALT lymphoma.

References

1. Isaacson PG. The MALT lymphoma concept updated. *Ann Oncol* 1995;6:319–20.
2. Harris NL, Jaffe ES, Stein H, Flandrin G, Muller-Hermelink HK, Vardiman J, et al. A revised European-American classification of lymphoid neoplasm: a proposal from the international lymphoma study group. *Blood* 1994;84:1361–92.
3. Wotherspoon AC, Dogliani C, Isaacson PG. Low-grade gastric B-cell lymphoma of mucosa-associated lymphoid tissue (MALT): a multifocal disease. *Histopathology* 1992;20:29–34.
4. Zucca E, Pinotti G, Roggrero, Comi MA, Pascarella A, Capella C, et al. High incidence of other neoplasms in patients with low-grade gastric MALT lymphoma. *Ann Oncol* 1995;6:726–8.
5. Noda T, Akashi H, Matsueda S, Katsuki N, Shirahashi K, Kojiro M. Collision of malignant lymphoma and multiple early adenocarcinomas of the stomach. *Arch Pathol Lab Med* 1989;113:419–22.
6. Kolve M, Fischbach W, Greiner A, Wilms K. Differences in endoscopic and clinicopathological features of primary and secondary gastric non-Hodgkin's lymphoma. German Gastrointestinal Lymphoma Study Group. *Gastrointest Endosc* 1999;49:307–15.
7. Caletti G, Barbara L. Gastric lymphoma: difficult to diagnose, difficult to stage? *Endoscopy* 1993;25:528–30.
8. Herbay AV, Schreiter H, Rudi J. Simultaneous gastric adenocarcinoma and MALT-type lymphoma in *Helicobacter pylori* infection. *Virchows Arch* 1995;427:445–50.
9. Ishihama T, Kondo H, Saito D, Yamaguchi H, Shirao K, Yokota T, et al. Clinicopathological studies on coexisting gastric malignant lymphoma and gastric adenocarcinoma: report of four cases and review of the Japanese literature. *Jpn J Clin Oncol* 1997;27:101–6.
10. Wotherspoon AC, Isaacson PG. Synchronous adenocarcinoma and low grade B-cell lymphoma of mucosa associated lymphoid tissue (MALT) of the stomach. *Histopathology* 1995;27:325–31.
11. Planker M, Fischer JT, Peters U, Borchard F. Synchronous double primary malignant lymphoma of low grade malignancy and early cancer (collision tumor) of the stomach. *Hepatogastroenterology* 1984;31:144–8.
12. Goteri G, Ranaldi R, Rezai B, Baccharini MG, Bearzi I. Synchronous mucosa-associated lymphoid tissue lymphoma and adenocarcinoma of the stomach. *Am J Surg Pathol* 1997;21:505–9.
13. Nakamura S, Aoyagi K, Iwanaga S, Yao T, Tsuneyoshi M, Fujishima M. Synchronous and metachronous primary gastric lymphoma and adenocarcinoma: a clinicopathological study of 12 patients. *Cancer* 1997;79:1077–85.
14. Cammarota G, Larocca LM, D'Ugo D, Persiani R, Cianci R, Nocente R, et al. Synchronous gastric adenocarcinoma and MALT lymphoma in a patient with *H. pylori* infection. Could the two neoplasms share a common pathogenesis? *Hepatogastroenterology* 2001;48:104–6.
15. Hardman WJ, Gal AA, Pascal RR. Gastric adenocarcinoma and low grade B cell lymphoma of mucosa associated lymphoid tissue. *South Med J* 1997;90:426–30.
16. Baron BW, Bitter MA, Baron JM, Bostwick DG. Gastric adenocarcinoma after gastric lymphoma. *Cancer* 1987;60:1876–82.
17. Chan AO, Chu KM, Yuen ST, Leung SY, Lam SK, Wong J. Synchronous gastric adenocarcinoma and mucosa-associated lymphoid tissue lymphoma in association with *Helicobacter pylori* infection: comparing reported cases between the East and West. *Am J Gastroenterol* 2001;96:1922–4.
18. Japanese gastric cancer association. Japanese classification of gastric cancer—second English edition. *Gastric cancer* 1998;1:10–24.
19. Lauren P. The two histological main types of gastric carcinoma: diffuse and so-called intestinal-type carcinoma. *Acta Pathol Microbiol Scand* 1965;64:31–49.
20. Manier JW, Reyes CN. Collision tumor of the stomach. *Gastroenterology* 1974;67:1011–5.
21. Kelly SM, Geraghty JM, Nealy G. *H. pylori*, gastric carcinoma and MALT lymphoma. *Lancet* 1994;343:418.
22. Kaffes A, Hughes L, Hollinshead J, Katelaris P. Synchronous primary adenocarcinoma, mucosa-associated lymphoid tissue lymphoma and a stromal tumor in a *Helicobacter pylori*-infected stomach. *J Gastroenterol Hepatol* 2002;17:1033–6.
23. Brocheriou I, Nahon S, Coffin B, Megraud F, Matuchansky C, Rambaud JC, et al. Association of a low grade MALT lymphoma and a slightly differentiated adenocarcinoma of the stomach. *Ann Pathol* 1997;17:109–12.
24. Muller S, Seifert E, Stolte M. Simultaneous MALT type lymphoma and early adenocarcinoma of the stomach associated with *Helicobacter pylori* gastritis. *Z Gastroenterol* 1999;37:153–7.
25. Zucca E, Bertoni F, Roggero E, Cavalli F. The gastric marginal zone B-cell lymphoma of MALT type. *Blood* 2000;96:410–9.
26. Farinha P, Gascoyne RD. *Helicobacter pylori* and MALT lymphoma. *Gastroenterology* 2005;128:1579–605.
27. Fischbach W, Dragosics B, Kolve-Goebeler ME, Ohmann C, Greiner A, Yang Q, et al. Primary gastric B-cell lymphoma: results of a prospective multicenter study. The German-Austrian Gastrointestinal Lymphoma Study Group. *Gastroenterology* 2000;119:1191–202.